

Supplementary article data

^{18}F -FDG microPET imaging differentiates between septic and aseptic wound healing after orthopedic implant placement

A longitudinal study of an implant osteomyelitis in the rabbit tibia

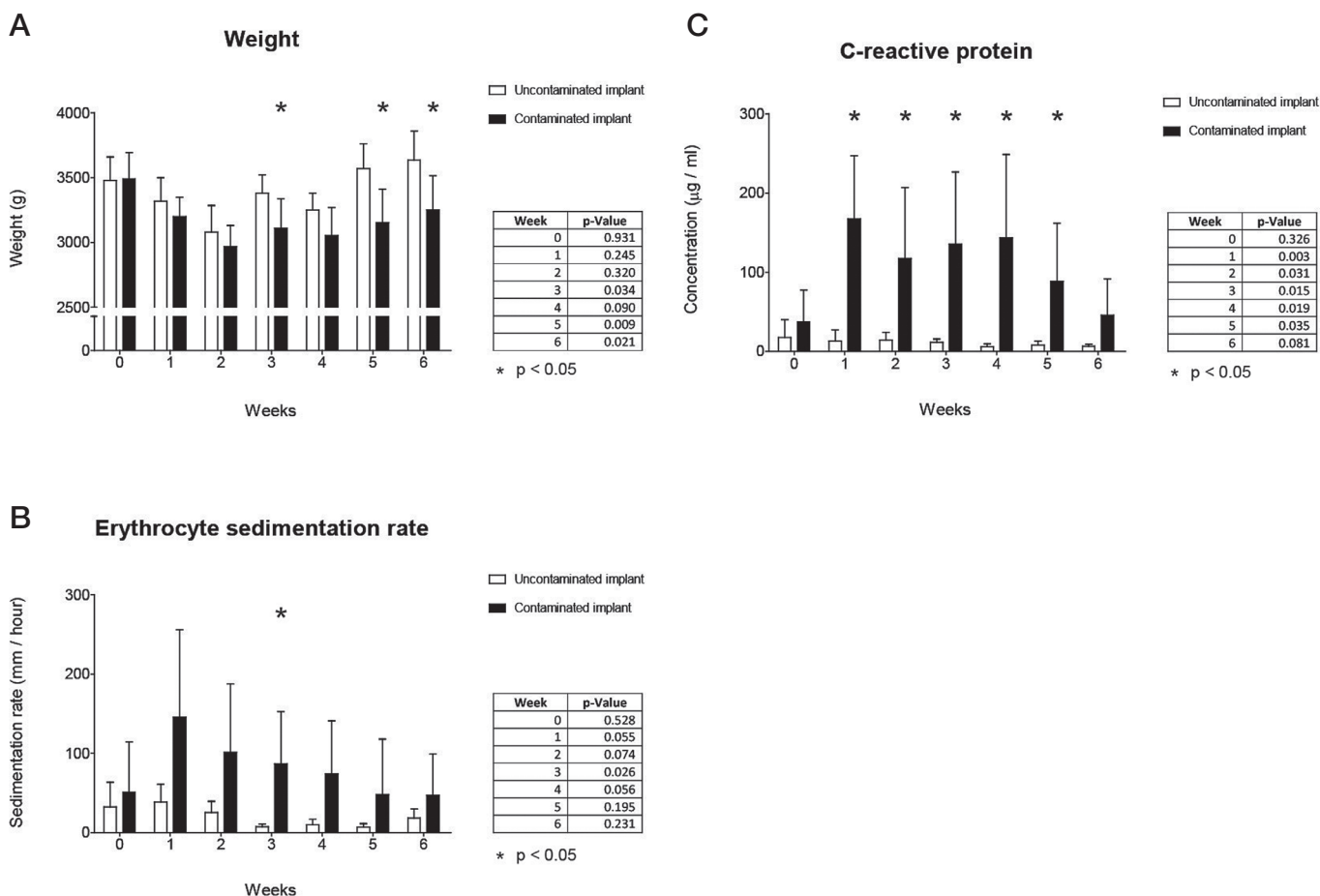
Jim CE Odekerken¹, Boudewijn T Brans², Tim JM Welting^{1*}, and Geert HIM Walenkamp^{1*}

¹Laboratory for Experimental Orthopaedics, Department of Orthopaedic Surgery, CAPHRI School for Public Health and Primary Care; ²Department of Nuclear Medicine, Maastricht University Medical Center, Maastricht, the Netherlands.

Correspondence: jim.odekerken@maastrichtuniversity.nl

*These authors contributed equally.

Submitted 13-07-30. Accepted 14-01-24



Supplementary Figure 1. A. Animal weight. B. Erythrocyte sedimentation rate. C. C-reactive protein levels. Asterisks indicate p-values < 0.05; the tables beside the graphs show the actual p-values. The error bars represent 95% confidence intervals.