

# Histology of an undisplaced femoral fatigue fracture in association with bisphosphonate treatment

## Frozen bone with remodelling at the crack

Per Aspenberg, Jörg Schilcher, and Anna Fahlgren

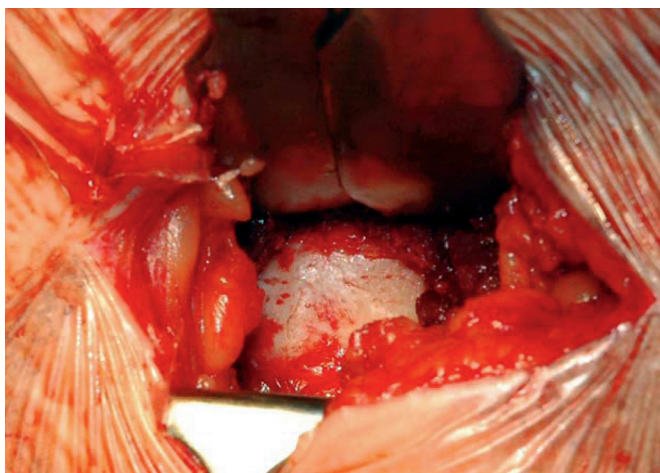


Figure 3. Photograph of the femoral crack as seen in the wound. Please use zoom to see it.




Figure 4. Specimen microCT of the fracture crack.

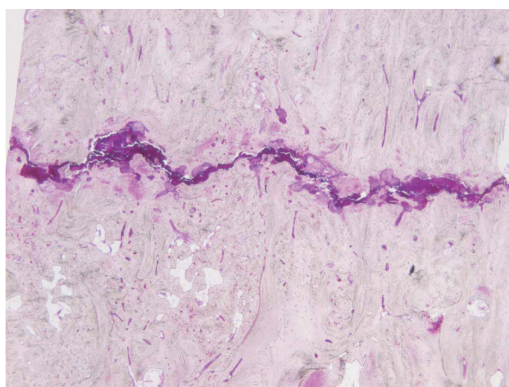


Figure 5. Overview of fracture crack with surrounding resorption cavities (basic fucsin, whole specimen staining)

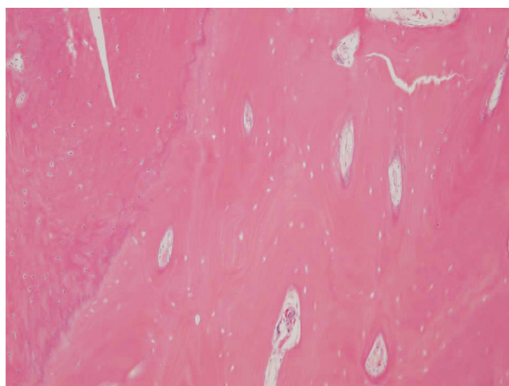


Figure 6. Cortex with empty osteocyte lacunae, contrasting to periosteal callus (left).

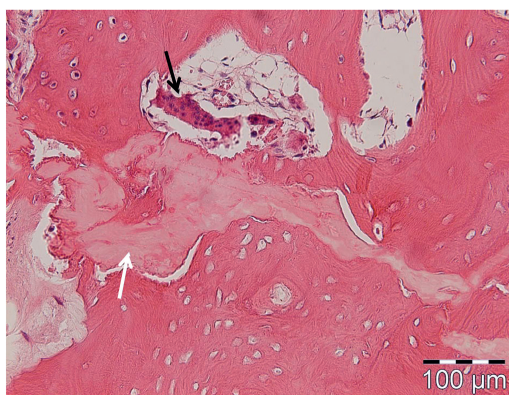


Figure 7. Area with amorphous disintegrated bone (white arrows), and giant osteoclast, detached from bone surface (black arrows).